

Does an extra kidney-ureter-bladder radiograph taken in the upright position during routine intravenous urography provide diagnostic benefit?

Kamil Gürel, Safiye Gürel, Melike Kalfaoğlu, Özlem Yılmaz, Ahmet Metin

PURPOSE

The aim of this prospective study was to assess the diagnostic benefit of taking a kidney-ureter-bladder (KUB) radiograph in an upright position during routine intravenous urography (IVU).

MATERIALS AND METHODS

Between February 2005 and September 2007, 170 consecutive patients were included in the study. A basal IVU exam consisted of pre-contrast supine KUB, post-contrast supine KUB at the 7th and 15th minutes, and supine pelvic radiographs with full bladder and post-voiding. When needed, additional compression and/or oblique radiographs were taken. In this study, for all patients, a post-contrast 15th minute upright KUB radiograph was added to IVU. Two consecutive radiographs taken at the 15th minute post-contrast in supine and upright positions were evaluated by consensus of 2 radiologists. Primary benefits were improved filling and emptying of the collecting system, and secondary benefits were nephroptosis and ascertaining diagnosis of phlebolith.

RESULTS

Of 170 patients, 337 kidneys and collecting systems ($n = 168$ right; $n = 169$ left) were examined. Improved filling, emptying of the collecting system, nephroptosis, ascertaining diagnosis of phleboliths were detected with the rates of 12.5%, 44.2%, 8.3%, and 3.2%, respectively. Improved filling was significant in the presence of hydronephrosis ($P < 0.05$) and ureterolithiasis ($P < 0.05$) on both sides. There was a positive correlation between both improved filling and presence of hydronephrosis, and improved filling and presence of ureterolithiasis. Emptying was significant in collecting systems that had no visible pathology on IVU ($P < 0.05$) on either side.

CONCLUSION

Upright KUB radiographs provide supplementary data about urine flow in terms of improved filling and emptying of the collecting system.

Key words: • urography • radiography • diagnosis

Intravenous urography (IVU) has long been the main imaging method for evaluation of urinary tract disease. However, other imaging modalities including ultrasonography, computed tomography (CT), and magnetic resonance imaging (MRI) have been used with increasing frequency to compensate for the limitations of IVU in the evaluation of urinary tract disease; in the last two decades, use of these modalities has surpassed use of the IVU (1). Recently the IVU has almost been regarded as outdated, and an “epitaph for the urogram” has been prepared (2). Despite the increased use of alternative modalities, each has limitations. The ideal “global” urinary tract examination remains controversial (1, 3, 4).

The IVU remains an appropriate examination for untangling complicated congenital anomalies, demonstrating surgical reconstructions of urinary tract, and following up patients with history of transitional cell carcinoma (2); it continues to be valuable in the follow-up evaluation of extracorporeal shock wave lithotripsy and endourologic therapy (e.g., Acucise endopyelotomy) (5).

Radiologists have the responsibility of optimizing technical aspects of the urinary tract imaging, and they must be available for real-time monitoring of the examination for problem solving. For example, adding images obtained with gravity maneuvers, such as prone or dependent oblique positioning, often assists in visualization of unopacified portions by improved filling of the ureters, especially in cases of obstruction (1, 6). Upright positioning may be an alternative gravity maneuver for improved filling.

As humans spend most of their time in upright position in routine daily life, the urinary system, like other systems, works in the upright position most of the time. Therefore, it is reasonable to expect that upright radiographs reflect the real physiologic status of urinary system better than supine radiographs in IVU. The aim of this prospective study was to assess the diagnostic benefit of taking a kidney-ureter-bladder (KUB) radiograph in an upright position during routine IVU.

Materials and methods

Between February 2005 and September 2007, a total of 208 patients were referred for IVU exam. All patients were considered for inclusion in this study. Exclusion criteria were inability to stand because of hemiparesis, early postoperative status, or cognitive inability to cooperate ($n = 4$); follow-up rather than initial IVU examination ($n = 20$); and elevated blood urea level and serum creatinine ($n = 14$). The remaining 170 patients were included in the study. Indications for IVU requests are given in Table 1. This study was approved by our institutional review board, and informed consent was obtained from all patients.

The patients underwent bowel preparation on the day prior to the study; this consisted of 2×75 mg sennoside suspension taken at 7 p.m.

From the Departments of Radiology (K.G. ✉ kamilgurel@hotmail.com, S.G., M.K., Ö.Y.), and Urology (A.M.), Abant İzzet Baysal University, İzzet Baysal School of Medicine, Bolu, Turkey.

Received 5 February 2008; revision requested 13 April 2008; revision received 6 May 2008; accepted 11 May 2008.

and 8 p.m. The patients were instructed to consume only fluids after 7 p.m. that day and on the morning of the IVU. After the pre-contrast KUB was evaluated, 1 mL/kg of non-ionic contrast material, which included 300 mgI/mL, was administered to the patient.

In our department, each step of a standard IVU exam is performed under the control and guidance of the radiologist. A basal standard IVU exam consists of 5 radiographs: pre-contrast supine KUB, post-contrast supine KUB at the 7th and 15th minutes, supine pelvic radiographs for full bladder, and supine post-voiding KUB. If any part of the collecting system is invisible or poorly visualized, then additional prone, compression, compression release, and/or oblique radiographs are taken until all parts are well documented. For all the patients included in this study, an additional post-contrast 15th-min upright KUB radiograph was obtained immediately

after the 15th-min supine KUB radiograph. The 15th minute was chosen for upright KUB radiograph because it coincides with sufficient opacification to visualize the pelvicalyceal system, ureters, and bladder. Supine KUB radiographs were obtained with 65–75 kVp, high milliamperes, and short exposure time. All parameters were kept constant except the milliamperes, which were increased by about 5–10 mAs for upright KUB. Two reviewers with 7 years of experience with IVU analyzed the 15th-min upright KUB; they then compared their findings, generating a consensus interpretation. The following findings were noted as diagnostic benefits:

1) Improved filling of collecting system: This was described as better delineation and visualization of the collecting system, either whole or partial, because of opacification on upright radiograph compared with the supine radiograph.

- 2) Emptying of collecting system: This was described as a reduction in the density of contrast material from the collecting system and/or reduction in the collecting system's luminal caliber for upright positioning.
- 3) Nephroptosis: This is the downward displacement of the kidney by ≥ 5 cm for an upright KUB radiograph (asymptomatic nephroptosis) (7). Distance from the iliac crest to the lower pole of the kidney was measured in both supine and upright 15th-min radiographs, and any displacement of the kidney ≥ 5 cm was noted as nephroptosis. When delayed excretion and hydronephrosis occurred with upright positioning, it was considered as pathologic nephroptosis.
- 4) Phleboliths are differentiated from calculi by their oval shape and radiolucent center. If disappearance of superpositioning of phleboliths from the lower part of the ureters was seen in upright KUB radiographs, this was noted as a secondary diagnostic benefit.

Improved filling and emptying were categorized as primary benefits, and detection of nephroptosis and better differentiation of phleboliths were categorized as secondary radiological benefits.

Statistical analysis was performed using the Statistical Package for Social Sciences (SPSS Inc., Chicago, Illinois, USA), version 11.0 software for Windows. Descriptive statistics were generated, and quantitative values were calculated using the chi-square test. Correlations between parameters were assessed using the Spearman correlation test. $P < 0.05$ was considered statistically significant in all cases.

Results

In all, 337 kidneys and collecting systems ($n_{\text{right}} = 168$; $n_{\text{left}} = 169$) from 170 patients (82 men, 88 women; mean age, 46.48 ± 16.98 years) were included in the study. One non-functional and two agenetic kidneys were excluded. There were 5 ($n_{\text{right}} = 2$, $n_{\text{left}} = 2$, $n_{\text{bilateral}} = 1$) duplicated collecting systems (complete duplication, 2; incomplete duplication, 3), which were accepted as single urinary systems for statistical analysis.

Table 1. Indications for intravenous urography requests

Indications	Number of patients
Urolithiasis	81
Collecting system dilatation on ultrasonography	27
Flank pain	17
Urinary tract infection	9
Renal cyst	5
UP-UV stenosis	5
Urinary anomaly	5
Incontinence	4
Bladder tumor	3
Hematuria	2
Prostatism, BPH	2
Non-functioning kidney	1
Pelvic pain	1
Previous urinary surgery	2
Renal tumor	1
Ureterocele	1
Renal sinus lipomatosis on ultrasonography	1
Bladder diverticula	1
Cystocele	2

BPH, benign prostatic hyperplasia; UP, ureteropelvic; UV, ureterovesical.

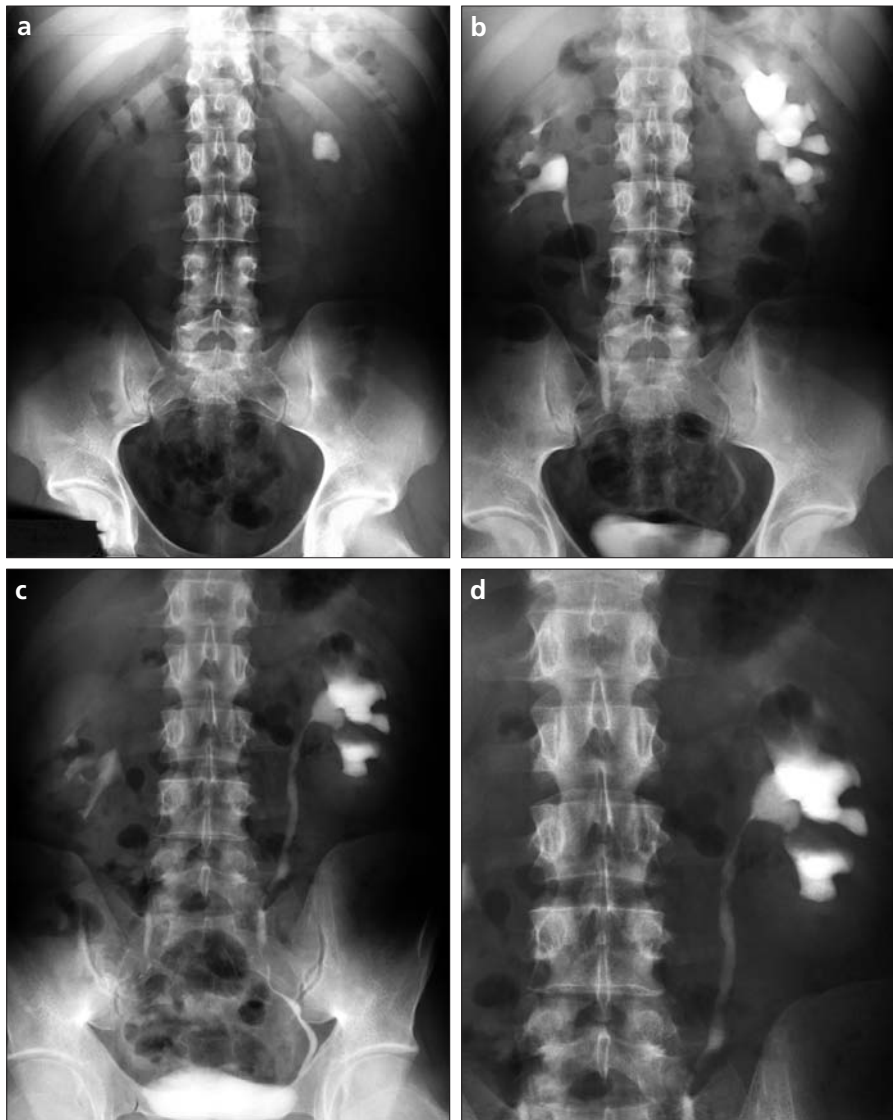


Figure 1. a–d. Better filling. Pre-contrast kidney-ureter-bladder (KUB) radiograph (a) shows a large radio-opacity in the left kidney region. In pyelogram phase (b–d), it is located in the left renal pelvis (b), causing moderate hydronephrosis (c). The proximal two-thirds of the left ureter is not visible in supine positioning (b), but an upright KUB radiograph (c) shows better filling of the ureter. The left ureter is completely visualized, which facilitates delineation of the narrowed uretero-pelvic junction (d), reflecting edema or stricture.

Diagnostic benefits of the 15th-min upright KUB were observed in 206 (61.1%) urinary systems; 182 systems had one diagnostic benefit, and 24 had

two diagnostic benefits (emptying accompanied with nephroptosis, 17; and emptying accompanied with phleboliths, 7) (Table 2).

Improved filling of collecting system

Of the 337 collecting systems, 42 (12.5%) ($n_{\text{bilateral}} = 5$, $n_{\text{unilateral}} = 32$ [$n_{\text{right}} = 18$, $n_{\text{left}} = 14$]) showed improved filling with upright positioning. Right (95.7% [22 of 23, $P < 0.001$]) and left (94.7% [18 of 19, $P < 0.001$]) collecting systems had improved filling with ≥ 1 accompanying pathologies (nephrolithiasis, ureterolithiasis, hydronephrosis, and hydroureteronephrosis). Distribution of improved filling according to accompanying pathology was as follows: on the right, 27.3% (9 of 33) nephrolithiasis ($P = 0.011$, $r = 0.195$); 40.0% (4 of 10) ureterolithiasis ($P = 0.013$, $r = 0.193$); 50.0% (12 of 24) hydronephrosis ($P < 0.001$, $r = 0.431$); and 28.6% (4 of 14) hydroureteronephrosis ($P = 0.091$, $r = 0.131$); on the left, 17.9% (7 of 39) nephrolithiasis ($P = 0.126$ [Fig. 1]); 33.3% (4 of 12) ureterolithiasis ($P = 0.020$, $r = 0.179$); 50.0% (12 of 24) hydronephrosis ($P < 0.001$, $r = 0.499$); and 20% (3 of 15) hydroureteronephrosis ($P = 0.261$; $r = 0.087$ [Table 3]). Collecting systems showing improved filling with > 1 pathology were as follows: nephrolithiasis-hydronephrosis ($n = 11$, $n_{\text{right}} = 4$, $n_{\text{left}} = 7$); ureterolithiasis-hydroureteronephrosis ($n_{\text{right}} = 1$); nephrolithiasis-ureterolithiasis ($n_{\text{right}} = 2$); and nephrolithiasis-ureterolithiasis-hydronephrosis ($n_{\text{left}} = 1$). There was a reasonable positive correlation between improved filling and the presence of hydronephrosis, and there was a weak positive correlation between improved filling and the presence of ureterolithiasis.

Emptying of collecting system

Of 337 collecting systems, 149 (44.2%) ($n_{\text{bilateral}} = 52$, $n_{\text{unilateral}} = 45$ [$n_{\text{right}} = 18$, $n_{\text{left}} = 27$]) showed emptying on upright KUB. Collecting systems with no remarkable pathology (51.9% [54 of 104] on the right and 54.7% [58 of 106] on the left) showed

Table 2. Benefit distribution by collecting systems in 170 patients

	Total number of systems	Benefit (-)	Number of systems with benefit (+)	Number of total benefits	Improved filling	Emptying	Nephroptosis	Phlebolith
Right collecting system	168	68	100	114	23	70	14	7
Left collecting system	169	63	106	116	19	79	14	4
Total	337	131	206	230	42	149	28	11

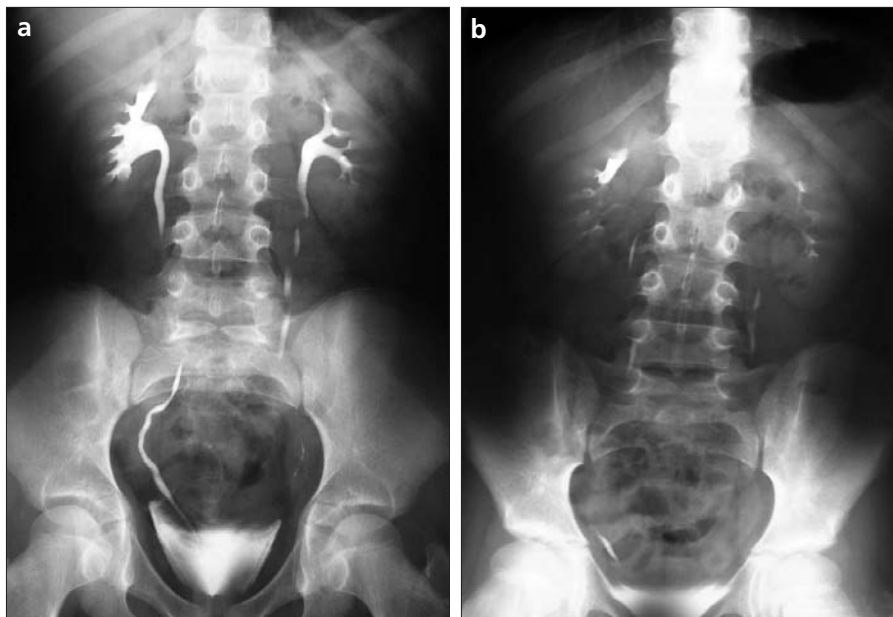


Figure 2. a, b. Emptying and improved filling. On the supine kidney-ureter-bladder (KUB) radiograph (a), there is minimal hydronephrosis and blunting of upper pole calyces in the right kidney, and other findings are unremarkable. The upright KUB radiograph (b) nicely illustrates bilateral emptying of the normal collecting system, but the right upper pole calyces remain filled with contrast, which indicates obstruction in the upper pole infundibulum.

emptying. Emptying was significant in collecting systems that had no pathology on IVU images ($P = 0.001$, $r = 0.265$; and $P = 0.007$, $r = 0.207$, respectively). Collecting systems showing emptying with accompanying pathology (nephrolithiasis, ureterolithiasis, hydronephrosis, and hydroureterone-

phrosis) comprised 77.1% (54 of 70) of the samples on the right and 73.4% (58 of 79) on the left. Distribution of emptying based on accompanying pathology was as follows: for the right, 27.3% (9 of 33) nephrolithiasis ($P = 0.061$); 30.0% (3 of 10) ureterolithiasis ($P = 0.440$); 20.8% (5 of 24) hydrone-

phrosis ($P = 0.025$, $r = -0.173$); and 28.6% (4 of 14) hydroureteronephrosis ($P = 0.299$); for the left, 38.5% (15 of 39) nephrolithiasis ($P = 0.634$); 25.0% (3 of 12) ureterolithiasis ($P = 0.045$, $r = -1.54$); 12.5% (3 of 24) hydronephrosis ($P = 0.002$, $r = -0.243$ [Fig. 2]); and 26.6% (4 of 15) hydroureteronephrosis ($P = 0.103$ [Table 3]). Results for collecting systems showing emptying with ≥ 1 pathology were as follows: nephrolithiasis-hydronephrosis ($n_{\text{right}} = 2$; $n_{\text{left}} = 3$); ureterolithiasis-hydroureteronephrosis ($n_{\text{right}} = 3$); and nephrolithiasis-ureterolithiasis ($n_{\text{left}} = 1$). Emptying was negatively correlated with the presence of hydronephrosis.

Nephrolithiasis was sometimes accompanied by ipsilateral hydronephrosis on the right (12 of 33) and left (17 of 39). In the presence of right-sided nephrolithiasis, 9 of 33 showed improved filling, and 9 of 33 showed emptying of the collecting system on the right; 7 of 39 showed improved filling and 15 of 39 showed emptying of the collecting system on the left.

Nephroptosis

Twenty-eight kidneys (8.3%) ($n_{\text{bilateral}} = 9$, $n_{\text{unilateral}} = 10$ [$n_{\text{right}} = 5$, $n_{\text{left}} = 5$]) were nephroptotic. A minimum 5-cm and maximum 10-cm movement was detected on both sides. The mean descent of nephroptotic kidneys was 6.4 ± 1.62 cm on the right and 6.5 ± 1.46

Table 3. Benefit distribution by bilateral pathology

	Right					Total	Left					Total
	Nephrolithiasis	Ureterolithiasis	Hydronephrosis	Hydroureteronephrosis	# with acc. path.		Nephrolithiasis	Ureterolithiasis	Hydronephrosis	Hydroureteronephrosis	# with acc. path.	
Benefit (-)	14	2	6	5	24	68	15	3	9	6	22	63
Improved filling	9	4	12	4	22	23 ^a	7	4	12	3	18	19 ^a
Emptying	9	3	5	4	16	70	15	3	3	4	21	79
Nephroptosis	1	1	1	1	2	14	1	1	0	1	3	14
Phlebolith	1	0	1	0	1	7	1	1	0	1	2	4
Total	33	10	24	14		168	39	12	24	15		169

with acc. path., number of systems with accompanying pathology.

^a Only one patient who had bilateral incomplete collecting system dilatation showed better filling without any accompanying pathology.

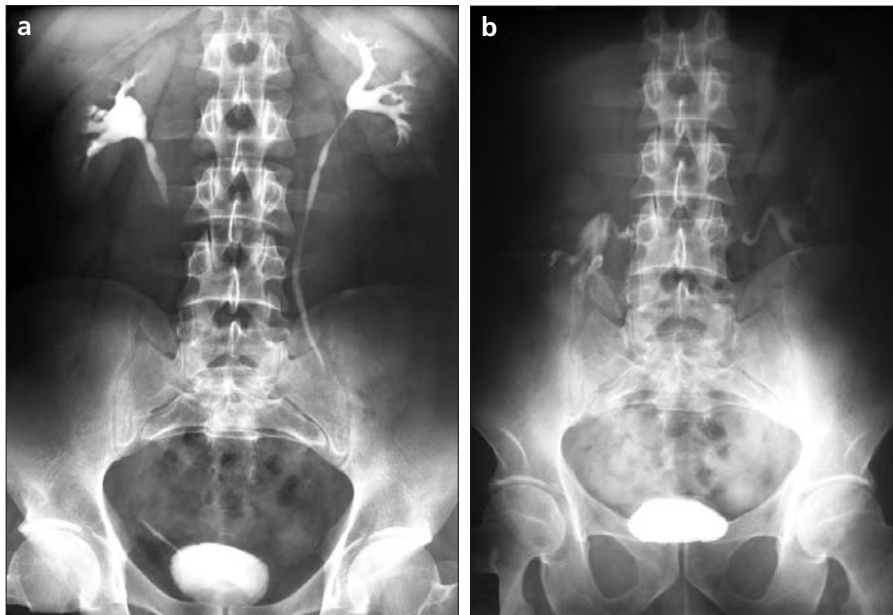


Figure 3. a, b. Nephroptosis. Supine (a) and upright (b) kidney-ureter-bladder radiographs show bilateral asymptomatic nephroptosis. The right and left kidneys have moved downward by 9 and 10 cm, respectively, in the upright positioning. Bilateral renal pelvises seem less visible due to the reduction of contrast material, and both ureters are invisible due to emptying (b).

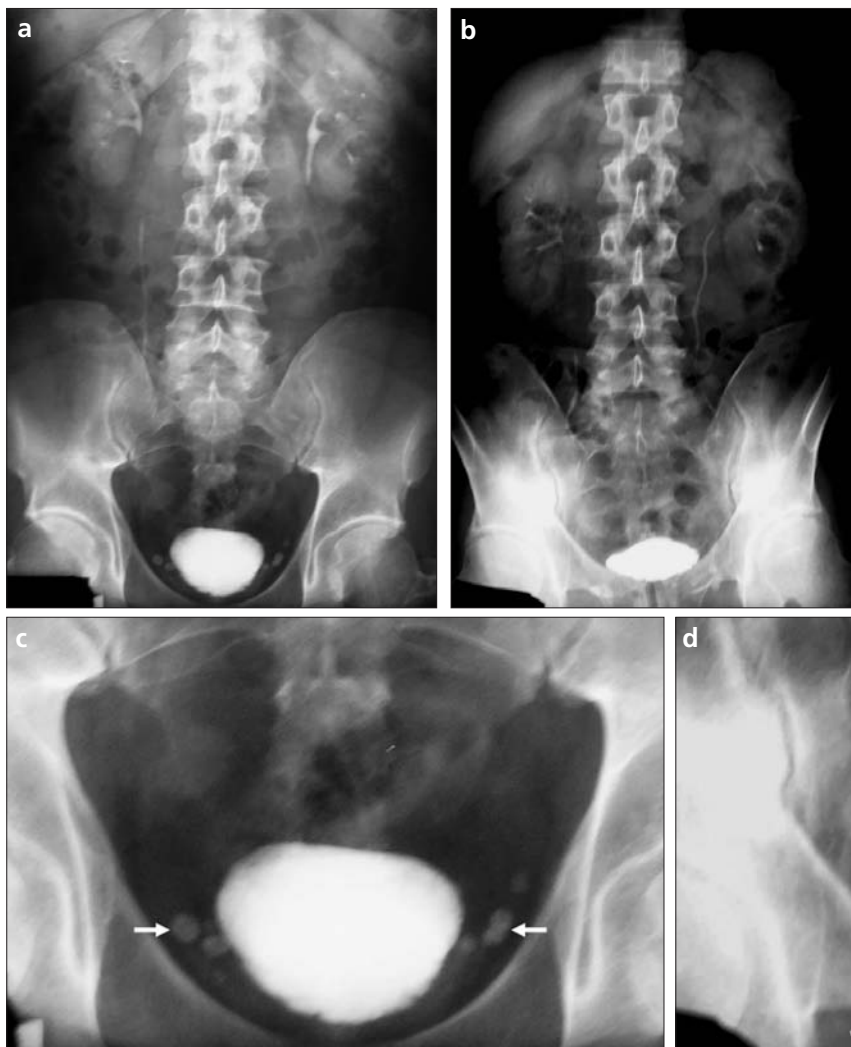

Figure 4. a–d. Ascertaining diagnosis of phleboliths. On kidney-ureter-bladder (KUB) radiographs (a–d), there are opacities in the small pelvis adjacent to the bladder with central lucencies, which strongly indicate phleboliths (white arrows). On supine KUB radiographs (a, c), their locations are suspicious for distal ureterolithiasis. On the upright KUB radiographs (b, d); it can be determined that those opacities (white arrows) are located outside the ureters (black arrow); note bilateral emptying of the pelvic calyceal systems with the upright positioning (b).

cm on the left. There was no pathologic nephroptosis; 61% (17 of 28) of nephroptotic kidneys (9 of 14 on the right [$P = 0.067$] and 8 of 14 on the left [$P = 0.403$]) showed emptying on upright KUB (Fig. 3). Nephroptosis occurred in 9 of 14 women on the right side and 8 of 14 on the left.

Phlebolith

A total of 42 (12.4%) phleboliths were detected in 337 collecting systems on supine KUB. Among 42 phleboliths, upright radiographs showed disappearance of superpositioning from the lower part of the ureters and resulted in the diagnosis of phleboliths in 11 (26.1%) patients, which was equivalent to 3.2% of all collecting systems (Fig. 4).

Discussion

Methods used for urinary imaging other than IVU have several advantages. Ultrasonography is preferred when urographic findings suggest a cyst, while CT is recommended when the findings suggest a solid lesion. MRI with gadolinium chelates is useful for analyzing some indeterminate renal masses in the evaluation of patients who have a significant risk for adverse reaction to iodinated contrast agents (1, 3). Non-enhanced helical CT easily detects urinary tract calculi and pro-

vides a sizeable amount of diagnostically relevant information (e.g., stone size, attenuation, stone composition, shape, location). Perinephric edema for ureteral obstruction and perinephric stranding for spontaneous passage of small stones are useful signs when found with CT. MR urography can demonstrate perirenal fluid in acutely obstructed kidneys (2). MR angiography and CT angiography have advantages over ultrasonography and IVU in evaluating many patients with renovascular hypertension and determining venous and arterial anatomy in potential donors (3).

There are several limitations of ultrasonography, CT, and MRI: lack of visualization for large portions of the urinary tract with ultrasonography, necessity of contrast agent administration and excretory images with CT, inability to visualize subtle urothelial abnormalities with sufficient spatial resolution with both CT and MRI, and insufficiency in visualizing calcifications with MRI (1). Additional disadvantages of MRI are inconspicuousness of small intrarenal calculi, susceptibility artifact due to metallic objects that interfere with the visualization of ureteral segments, flow-related artifact in some sequences, and interference of hemorrhage into renal collecting system with static-fluid MR urography (8). The patient effective dose, and therefore radiation risk, of CT urography is 1.5 times that of conventional urography. The increased radiation risk from a CT urography compared with an IVU should be considered in the context of the amount of information that is necessary for the diagnostic task. Radiation risk is increased for smaller patients in CT urography and for larger patients in IVU (5). Although CT falls short of IVU in the evaluation of urothelium, helical CT technology continues to evolve with introduction of multidetector row scanning (MDCT) (3, 9); MDCT may eventually replace IVU for the evaluation of hematuria (2, 4). Finally, there is not an optimum or ideal examination technique for CT urography (10) or MR urography. Examination techniques must be constructed according to suspected pathology of the patient and urinary system status.

Although advances in imaging technology have given CT and MR urography advantages over IVU, many cent-

ers still use IVU as a part of routine radiological practice. Therefore, techniques or modifications for improving application and diagnostic capabilities of IVU should still be considered.

In our study, improved filling was detected for 95.2% (40 of 42) of the group that had one or more accompanying pathologies such as calculi or collecting system dilatation. Improved filling of the ureters was significant ($P < 0.001$ on both sides) when hydronephrosis was present, and hydronephrosis was negatively correlated with emptying ($P = 0.025$, $r = -0.173$, on the right; $P = 0.002$, $r = -0.243$, on the left) (possibly due to an obstruction). Therefore, improved filling of ureters might occur not only because of emptying but also because of delivery of the pooled contrast agent bolus from the hydronephrotic pelvicalyceal system into the ureters. The radiologic reflection of this finding was the coexistence of improved filling of ureters and the persistence of hydronephrosis in upright positioning.

Improved filling of ureters was significant ($P = 0.013$ on the right, $P = 0.020$ on the left) in the presence of ureteral calculi, but there was a weak correlation ($r = 0.193$ and 0.179 , respectively) between them. It is concluded that ureteral calculi causing partial obstruction allowed passage of contrast material without causing prominent ureteral dilatation in supine positioning. In the case of upright positioning, gravity caused an increase in the flow rate of urine passing from the same area and causing a complete obstruction at the site of calculi. Gravity maneuvers, such as prone or dependent oblique positioning, often assist in visualization of unopacified portions by improving filling of the ureters, especially in cases of obstruction (1, 6). Thus, upright positioning might be another alternative gravity maneuver for improved filling.

It might be assumed that a normal collecting system which has no obstructive pathology empties by upright positioning. However, in our study, only 53.3% of normal collecting systems showed emptying. This finding raised questions: First, what is the meaning of non-emptying for normal collecting systems (is it an abnormality that can not be detected on supine IVU; is it a sign of subtle pathology that has not appeared or

disappeared completely clinically and radiologically; or is it a physiological reflex mechanism that prevents immediate emptying of urine or contrast only with the help of peristaltic waves)? Second, if non-emptying has no pathologic significance, what is the meaning of emptying of 53.3% of normal collecting systems (is it a radiological sign of normal physiological variance)? We could not clarify these points with our current data, and we think this finding needs further investigation. To our knowledge, "emptying" and "non-emptying" are described only for the bladder and are used as "full bladder" and "post voiding" in the current literature, but all data in the literature deal only with the presence or degree of "opacification" or "filling" of the pelvicalyceal system and ureters. We use the terms "emptying" and "non-emptying" of the pelvicalyceal system and ureters in the literature for the first time depending on upright KUB, which can be assumed to reflect the real physiologic status of urinary system in a person's routine daily life. To our knowledge, upright KUB is reported to be useful only for diagnosis of milk of calcium (11) and nephroptosis (7) in current literature, while upright KUB has not been used before in the evaluation of emptying and improved filling of the collecting system, as in our study.

Nephropexy was a common urologic procedure being performed at the beginning of the 20th century. However, it rapidly became clear that most patients with nephroptosis were asymptomatic and required no therapy. It is reported that nephroptosis is present in 20% of IVUs of women (7). In our study group, approximately 10% of women had nephroptosis; none had pathologic nephroptosis. In the current literature, the gold standard for diagnosis of nephroptosis is the conventional radiograph taken in an upright position. Rapid increase in the availability of CT and MRI and the tendency of radiologists to prefer CT or MR urography carries the risk of missing pathologic nephroptosis in patients with unexplained pain, hematuria, and hypertension.

Phleboliths are differentiated from calculi by their oval shapes and radiolucent centers; however, upright positioning makes differentiation easier by modifying superpositioning of dif-

ferent structures. In 26% of collecting systems with phleboliths, diagnoses were confirmed with upright positioning, because it became obvious in upright radiographs that phleboliths were outside the ureters. The upright radiograph is not essential for diagnosis of phleboliths, but it helps in the diagnosis—a minor benefit along with major benefits.

This article is a descriptive, non-comparative report of our experience obtaining an upright KUB during routine IVU. There are several limitations of this study. First, it included neither a control group of standard IVU that could be compared with IVU combined with upright radiographs, nor were data collected about the necessity for additional compression or other gravity-related films. These are weaknesses for two reasons. If there was a control group in which upright radiographs were not taken, then both the impact of taking an upright KUB as a means for decreasing or increasing the total number of routine radiographs could have been documented (it can be speculated that IVU with upright KUB might decrease the number of additional compression or other gravity related films needed). Also, the patient radiation dose might have been estimated. Another limitation of our study was that our aim was to evaluate if an upright KUB provides benefits or makes a difference in the diagnostic value of IVU within its limits, so we planned to make a comparison between conventional IVU (15th minute supine KUB) and its modified version (15th minute upright KUB). However, we did not have a matched or unmatched control group having CT or MR urography. There are, however, several studies comparing CT urography and MR urography with standard IVU exams. It was reported that scanning of the kidneys during compression and of the ureters during compression release on CT urography provided equal or better opacification

of collecting systems with respect to IVU (12). Static-fluid MR urography is superior to IVU in showing the cause of obstruction when a non-functioned kidney is present (13, 14). Diuretic contrast-enhanced MR urography is an alternative to IVU for imaging the nondilated urinary tract (15). For our study, the presence of a control group with CT or MR urography would have been much better in order to evaluate the value of upright KUB with respect to both its conventional form and advanced imaging methods, determine whether this modification provides advantages to IVU over CT or MR urography, and see if IVU is really outdated. Further studies comparing this modified IVU method with CT urography and MR urography are needed.

Although comparison of upright KUB films with compression and/or compression release films was not a part of this study, we can still reach some conclusions. Based on the positive correlation between improved filling with hydronephrosis and calculi, and the negative correlation between emptying and hydronephrosis, we can conclude that an upright KUB can replace compression and/or compression release films, especially in cases in which abdominal compression is contraindicated, such as abdominal aortic aneurysm, other abdominal masses, recent abdominal surgery, or severe abdominal pain (1, 8).

In conclusion, improved filling or visualization of unopacified portions of the collecting system can be achieved by upright positioning of the patient during IVU as in other gravity maneuvers. Appreciable changes are demonstrated on the post-contrast 15th minute upright KUB radiograph that verify improved filling and emptying of urine flow in the collecting system, so it may be used as a gravity maneuver. However, further studies are needed before its routine introduction into IVU.

References

1. Dyer RB, Chen MYM, Zagoria RJ. Intravenous urography: technique and interpretation. *Radiographics* 2001; 21:799–821.
2. Amis ES. Epitaph for the urogram. *Radiology* 1999; 213:639–640.
3. Hattery RR, King BF. Invited commentary. *Radiographics* 2001; 21:822–824. [commentary on: Dyer RB, Chen MYM, Zagoria RJ. Intravenous urography: technique and interpretation. *Radiographics* 2001; 21:799–821].
4. Nawfel RD, Judy FP, Schleipman AR, Silverman SG. Patient radiation dose at CT urography and conventional urography. *Radiology* 2004; 232:126–132.
5. Becker JA, Pollack HM, McClennan BL. Urography survives. *Radiology* 2001; 218:299.
6. Kowalchuk RM, Banner MP, Ramchandani P, Forman HP. Efficacy of prone positioning during intravenous urography in patients with hematuria or urothelial tumor but no obstruction. *Acad Radiol* 1998; 5:415–422.
7. Hoenig DM, Hemal AK, Shalhav AL, Clayman RV. Nephroptosis: a disparaged condition revisited. *Urology* 1999; 54:590–596.
8. Leyendecker JR, Barnes CE, Zagoria RJ. MR urography: techniques and clinical applications. *Radiographics* 2008; 28:23–46.
9. Kawashima A, Vrtiska TJ, LeRoy AJ, Hartman RP, McCollough CH, King BF. CT urography. *Radiographics* 2004; 24: S35–S58.
10. Nolte-Ernsting C, Cowan N. Understanding multislice CT urography techniques: many roads lead to Rome. *Eur Radiol* 2006; 16:2670–2686.
11. McGeorge A, Smith JS, Orr PS, Corbett RH. The value of erect film in intravenous urography. *Br J Urol* 1984; 56:340–341.
12. Heneghan JP, Kim DH, Leder RA, DeLong D, Nelson RC. Compression CT urography: a comparison with IVU in the opacification of the collecting system and ureters. *J Comput Assist Tomogr* 2001; 25:343–347.
13. Jung P, Brauers A, Nolte-Ernsting CA, Jakse G, Gunter RW. Magnetic resonance urography enhanced by gadolinium and diuretics: a comparison with conventional urography in diagnosing the cause of ureteric obstruction. *BJU Int* 2000; 86:960–965.
14. Erdogmus B, Bozkurt M, Bakir Z. Diagnostic value of HASTE technique and excretory MR urography in urinary system obstructions. *Tani Girisim Radyol* 2004; 10:309–315.
15. El-Diasty T, Mansour O, Farouk A. Diuretic contrast-enhanced magnetic resonance urography versus intravenous urography for depiction of nondilated urinary tracts. *Abdom Imaging* 2003; 28:135–145.